



REPAIR™

Effectively manage peri-implantitis patients with a patient-preferred, minimally invasive therapy.

BIOLASE
Global Leadership in Lasers



*A Minimally Invasive Protocol for
Effective Management of Peri-Implantitis*

REPAIR Implant™ provides clinicians a scientifically advanced method to assist in the management of peri-implantitis. Utilizing the WaterLase iPlus and patented Radial Firing Perio Tips™ (RFPT), REPAIR Implant provides a safe, effective laser treatment protocol that patients accept.

- + Easy access to the implant surface
- + Minimally invasive
- + Closed flap protocol can be used for early peri-implantitis
- + Treat site-specific or full-mouth cases for greater flexibility in treatment planning
- + Supported by clinical evidence and scientific research
- + Versatile YSGG laser ideal for comprehensive clinical use
- + Laser photoacoustic properties effectively debride the implant surface



REPAIR™

WATERLASE® ER,Cr:YSGG PERI-IMPLANTITIS REGIMEN

REPAIR Implant is the first definitive step-by-step protocol for using an Er,Cr:YSGG laser to assist in the management of early, moderate and severe peri-implantitis. It consists of three phases: pre-surgical, surgical and post-surgical.

PHASE I: PRE-SURGICAL PHASE

All patients should have a comprehensive examination/evaluation including data collection of periodontal charting and radiographs, medical and dental history, and risk assessment.

Phase I treatment is implemented for removal of supra- and subgingival biofilm and calculus through scaling and root planing (S/RP) and the initiation and evaluation of oral hygiene compliance. Remove the crown and abutment, when possible, and a healing cap should be placed on the affected implant body. This allows for vertical laser tip access to the implant. Flap reflection may be necessary for complete access to threads in moderate to severe cases.

PHASE II: SURGICAL PHASE

Phase II surgical treatment plan is developed based on the re-evaluation of periodontal inflammation and oral hygiene compliance. The surgical plan can be for a single implant or multiple sites.

WaterLase*®*iPlus™ Pre-set Settings

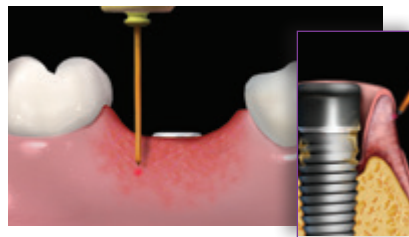
Tip: RFTP5
Power: 1.5W
Air/Water: 40%/50%
Pulse rate: 30 Hz
H mode

Tip: RFTP5
Power: 1.5W
Air/Water: 40%/50%
Pulse rate: 30 Hz
H mode

1

OUTER POCKET DE-EPITHELIALIZATION

Outer pocket gingival epithelium is re-moved from the free gingival margin down to a width at least equal to the pocket depth.

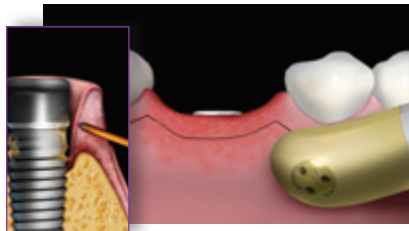


2

GINGIVECTOMY (AS NEEDED)

A gingivectomy should only be performed if pseudo-pocketing is present.

Ensure you do not compromise adequate attached gingivae.

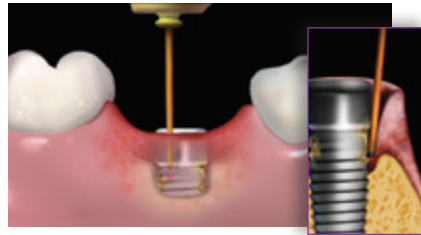


REPAIR™ WATERLASE PERI-IMPLANTITIS REGIMEN CONTINUED

3

SULCULAR DEBRIDEMENT / DEGRANULATION

The epithelium should be removed and should be completed apically, from the free gingival margin down to the osseous level. All granulation tissue is removed. Gingival margin can be retracted as a mini-flap for access.

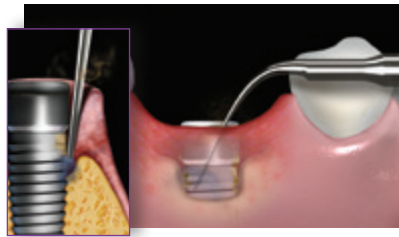


Tip: RFPT5
Power: 1.5W
Air/Water: 40% / 50%
Pulse rate: 30 Hz
H Mode

4

DEBRIDEMENT OF IMPLANT

Conventional treatment with ultrasonics (Use implant-safe tips. Please consult your implant manufacturer for recommend-ed ultrasonic tips.) to osseous levels. Upon completion, place a radial firing tip circum-ferentially beginning at the coronal surface of the first thread exposed and moved apically.



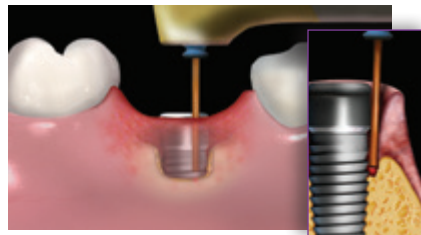
After Ultrasonic Treatment

Tip: RFPT5
Power: 1.5W
Air/Water: 40% / 50%
Pulse rate: 30 Hz
H Mode

5

BONE DECORTICATION

Re-contour osseous defects and stimulate bone regeneration. Hold tip parallel to implant surface and gently tap all the way down to and into bone, retracting slightly and repeating all the way around the implant. If necessary, change angle of laser tip and treat into the walls of infrabony defects.

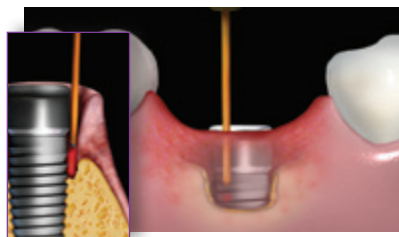


Tip: MZ6
Power: 2.5W
Air/Water: 70% / 80%
Pulse rate: 30 Hz
H mode

6

SULCULAR DEBRIDEMENT

Remove residual debris and induce blood coagulation.

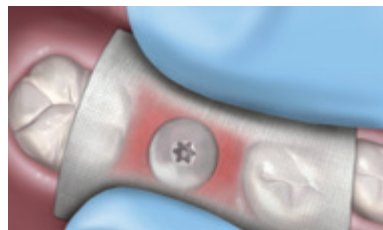

Tip: RFPT5
Power: 1.5W
Air/Water: 10% / 10%
Pulse rate: 30 Hz
H Mode

7

COMPRESS WITH 2X2 GAUZE

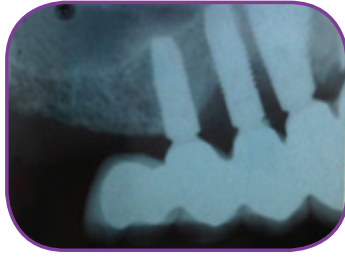Compress surgical site with wet 2x2 gauze for 3-5 minutes.



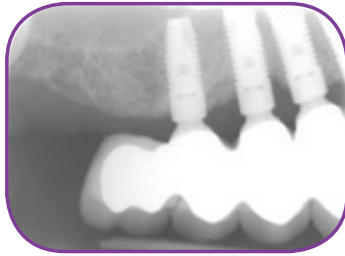
PHASE III: POST-SURGICAL PHASE

- IMMEDIATE POST-OPERATIVE: Brush teeth lightly with soft brush and use mouth rinse to supplement brushing if discomfort exists.
- ONE WEEK AFTER LASER TREATMENT: Gently clean between teeth using an interproximal brush dipped in mouthwash.
- NO PROBING for at least 3 months, at which time a supragingival scaling is completed.

CASE 1 – Courtesy of Dr. Rana Al-Falaki

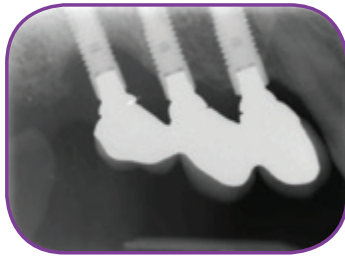


BEFORE

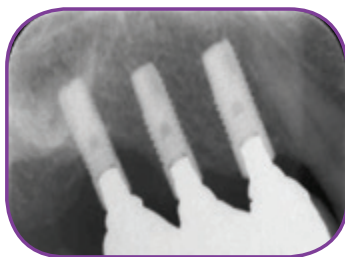


1 YEAR AFTER FLAPLESS TECHNIQUE

CASE 2 – Courtesy of Dr. Rana Al-Falaki



BEFORE



20 MONTHS AFTER

“The WaterLase iPlus is an integral part of every procedure I do. The results we achieve are outstanding, with so much less stress, so much more fun and so much more comfort for patients.”

— Dr. Rana Al-Falaki
London, UK



CLINICAL EVIDENCE

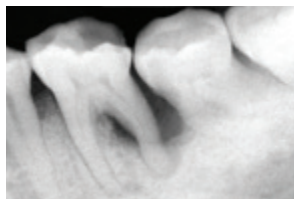- Prathapachandran J, Suresh N, Management of peri-implantitis; Dent Res J (Isfahan). 2012 Sep-Oct; 9(5): 516-521
- Mombelli A, Muller N, Cionca N, The epidemiology of peri-implantitis; Clin Oral Implants Res, 2012 Oct 23 Suppl 6:67-76
- Jepsen S, Berglundh et al, Primary prevention of peri-implantitis: managing peri-implant mucositis. J Clin Periodontol, 2015 April; 42 Suppl 16:S152-7
- Rosen P, Clem D, Cochran D et al, Peri-mucositis and peri-implantitis: a current understanding of their diagnoses and clinical implications; J Periodontol 2013; 84(4): 430-443
- Lindhe J, Meyle J. Peri-implant diseases: Consensus report of the Sixth European Workshop on Periodontology. J Clin Periodontol 2008;35(Suppl. 8):282-285.)
- Renvert S, Polyzois I, Persson GR Treatment modalities for peri-implant mucositis and peri-implantitis. Am J Dent. 2013 Dec;26(6):313-8.
- Kotsivilis S, Karoussis IK, Trianti M, Fourmousis I. Therapy of peri-implantitis: a systematic review. J Clin Periodontol 2008;35(7):621-9.
- Kelbauskiene, S., Baseviciene, N., Goharkhay, K., Moritz, A. & Machiulskiene, V. (2011) One-year clinical results of Er,Cr:YSGG laser application in addition to scaling and rootplaning in patients with early to moderate periodontitis. Lasers Med Sci 26, 445–452.10.1007/s10103-010-0799-4
- Dyer, B. & Sung, E.C. (2012) Minimally-invasive Periodontal Treatment Using the Er,Cr:YSGG Laser. A 2-year Retrospective Preliminary Clinical Study. Open Dent J 6, 74–78. 10.2174/1874210601206010074
- Dederich D, Periodontal bone regeneration and the Er,Cr:YSGG: a case report Open Dent J. 2013;7:16-19
- Mailloa J1, Lin GH, Chan HL, Maceachern M, Wang HL. Clinical Outcomes of Using Lasers for Peri-Implantitis Surface Detoxification: A Systematic Review and Meta-Analysis. J Periodontol. 2014 Jan 30. [Epub ahead of print] DOI: 10.1902/jop.2014.130620
- Deppe H, & Henning Horch H, Laser applications in oral surgery and implant dentistry Lasers Med Sci (2007) 22:217–221
- Kotsakis G, Konstantinidis I, Karoussis I et al. A systematic review and meta-analysis of the effect of various laser wavelengths in the treatment of peri-implantitis J Periodontol. 2014 Jan 30. [Epub ahead of print] DOI: 10.1902/jop.2014.130610
- Meyle J. Mechanical, chemical and laser treatments of the implant surface in the presence of marginal bone loss around implants Eur J Oral Implantol. 2012;5 Suppl:S71-81.
- Aoki A et al; Periodontal and peri-implant wound healing following laser therapy. Periodontology 2000 (68), 2015; 217-269
- Riziou M, Evensole R, Kimmel A et al Effects of Er,Cr:YSGG lasers on mucocutaneous soft tissues Oral Surg Oral Med Oral Path Radiol Endod. 1996; 82:386-395
- Zaffe D, Viatile M, Martignone A et al Morphological, histochemical and immunocytochemical study of CO2 and Er:YAG laser effects on oral soft tissues Photomed Laser Surg 2004; 22(3): 185-189
- Parker S, Laser: tissue interaction and its application in clinical dentistry Int J Laser Dent 2011; 1(1):1-8
- Esposito M, Grusovin MG, Kakisis I, Coulthard P, Worthington HV. Interventions for replacing missing teeth: treatment of perimplantitis. Cochrane Database Syst Rev 2008(2):CD004970.
- Ntrouka VI, Slot DE, Lourpoulou A, Van der Weijden F. The effect of chemotherapeutic agents on contaminated titanium surfaces: a systematic review. Clin Oral Implants Res 2011;22(7):681-90.0
- Tosun E, Tasar F, Strauss R, Gulmez D. Comparative Evaluation of Antimicrobial Effects of Er:YAG, Diode, and CO2 Lasers on Titanium Discs: An Experimental Study;
- Kreisler M, Kohnen W, Marinello C, et al. Bactericidal effect of the Er:YAG laser on dental implant surfaces: An in vitro study. J Periodontol 2002;73:1292-1298.
- Ando Y, Aoki A, Watanabe H et al, Bactericidal effects of erbium YAG on periodontopathic bacteria Lasers Surg med 1996;19:190-200
- Schoop U, Kluger W, Moritz A, Nedjelik N, et al Bactericidal Effect of Different Laser Systems in the Deep Layers of Dentin Lasers in Surgery and Medicine 35:111–116 (2004)
- Eberhard J, Ehlers H, Falk W, Acil Y, Albers HK, Jepsen S. Efficacy of subgingival calculus removal with ErYAG laser compared to mechanical debridement in an in situ study. J Clin Periodontol. 2003;30(6):511–8.
- Folwaczny M, Aggstaller H, Mehi A, Hickel R. Removal of bacterial endotoxin from root surface with Er:YAG laser. Am J Dent. 2003;16(1):3–5
- Aoki A, Sasaki K, Watanabe H et al. Lasers in nonsurgical periodontal therapy Periodontology 2000, 2004; 36:59-97
- Cobb CM. Lasers in periodontics a review of the literature. J Periodontol. 2006;77(4):545–64
- Krause F, Braun A, Brede O, Eberhard J, Frentzen M, Jepsen S. Evaluation of selective calculus removal by a fluorescence feedback-controlled Er YAG laser in vitro. J Clin Periodontol. 2007;34(1):66–71.
- Takasaki AA, Aoki A, Mizutani K, Kikuchi S, Oda S, Ishikawa I. Er:YAG laser therapy for peri-implant infection: A histological study. Lasers Med Sci 2007;22:143-157.
- Schwarz F, Jepsen S, Hertzen M, Sager M, Rothamel D, Becker J(2006) Influence of different treatment approaches on nonsubmerged and submerged healing of ligature induced peri-implant lesions. An experimental study in dogs. J Clin Periodontol 33:584–595
- Schwarz F, Bieling K, Nuesry E, Sculean A, Becker J. Clinical and histological healing pattern of peri-implantitis lesions following non-surgical treatment with an Er:YAG laser. Lasers Surg Med 2006;38(7):663-71.
- Giannelli M, Pini A, Formigli L, Bani D. Comparative in vitro study among the effects of different laser and LED irradiation protocols and conventional chlorhexidine treatment for deactivation of bacterial lipopolysaccharide adherent to titanium surface. Photomed Laser Surg. 2011;29(8):573–80.
- Persson G, Roos-Jansaker A, Lindahl C, Renvert S (2011) Microbiological results after non surgical erbium doped yttrium, aluminium, and garnet laser or air-abrasive treatment of peri-implantitis: a randomized clinical trial J Periodontol 82, 1267-1278
- Schwarz F, Sahm N, Iglhaut G et al, Impact of the method of surface debridement and decontamination on the clinical outcome following combined surgical therapy of peri-implantitis: a randomized controlled clinical study J Clin Periodontol 2011; 38: 276–284
- Schwarz F, Hegewald A, John G, N, Becker J, Four-year follow-up of combined surgical therapy of advanced peri-implantitis evaluating two methods of surface decontamination J Clin Periodontol 2013; 40: 962–967 doi: 10.1111/jcpe.12143
- Miller R, Treatment of the contaminated implant surface using the Er,Cr:YSGG laser Implant Dentistry 2004 13(2):165-169
- Azzeh M, Er,Cr:YSGG laser assisted surgical treatment of peri-implantitis with 1 year re-entry and 18 month follow up J Periodontol 2008; 79(10):2000-2005
- Smith LP, Rose T, Laser explantation of a failing endosseous dental implant Aus Dent J 2010; 55:219-222
- Olivi G, Laser use in endodontics evolution from direct laser irradiation to laser activated irrigation J Laser Dent 2013; 21(2),58-71
- Al-Falaki R, The Use of the Er,Cr:YSGG laser as an adjunct of root surface instrumentation in the management of Chronic Periodontitis compared to root surface instrumentation alone: a retrospective study. J Clin Periodontol 2015 doi:10.1111/jcpe.12398, pg 39
- Al-Falaki R, Wadia R, Hughes F: Use of Er,Cr:YSGG laser as an adjunct to root surface instrumentation: analysis of an extended case series. J Clin Periodontol 2015 doi:10.1111/jcpe.12399, pg 275
- Al-Falaki R, Hughes F, Cronshaw M: Non-surgical management of peri-implantitis using Er,Cr:YSGG laser: one year follow up case series. J Clin Periodontol 2015 doi: 10.1111/jcpe.12399, pg 439-440
- Al-Falaki R, Hughes F, Cronshaw M; Treatment outcome following use of the Er,Cr:YSGG laser in the non-surgical management of peri-implantitis: a case series. British Dental Journal 2014 (217), 453-457 doi: 10.1038/sj/bdj.2014.910

VERSATILE. TREAT SOFT-TISSUE, IMPLANTS, TOOTH ROOT, AND BONE.

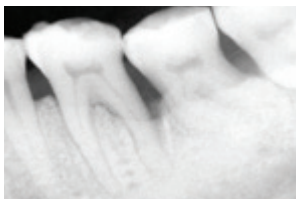
The WaterLase iPlus combines YSGG laser energy and a patented spray of water to cut soft-tissue and bone, with reported benefits such as less swelling and post-op sensitivity, an optimal patient experience and greater case acceptance.

In soft-tissue mode, the laser energy penetrates into tissues to seal blood vessels as it cuts, providing excellent hemostasis, which in turn provides you with a better field of vision during surgery.

Courtesy of Dr. Bret Dyer



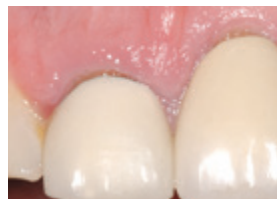PRE-OP



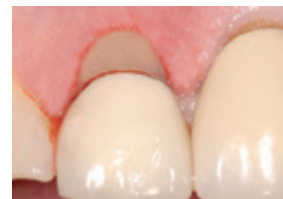3 YEARS POST-OP

PERIODONTAL DISEASE

Introducing REPAIR Perio™, a minimally invasive protocol for optimal periodontal patient management. Utilizing the WaterLase iPlus and patented Radial Firing Perio Tips, REPAIR Perio provides a safe, effective laser treatment protocol that patients accept at a cost your practice can afford.



PRE-OP

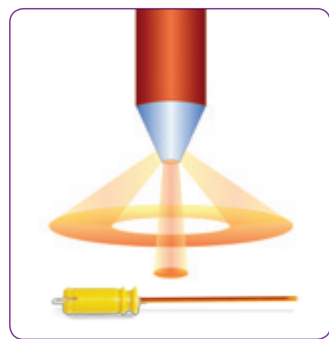


IMMEDIATE POST-OP

OSSEOUS CROWN LENGTHENING FOR SAME DAY REFERRALS

Minimize tissue displacement and flap preparation in osseous crown lengthening. It assists in performing an externally beveled gingivectomy, shaping the free gingival margin, troughing, and recontouring or smoothing bone.

INNOVATIVE. SOLVE YOUR POCKET ACCESS CHALLENGES.



THE RADIAL FIRING PERIO TIP

Our patented Radial Firing Perio Tip (RFPT) is superior to traditional laser tips used for periodontal therapy, featuring a unique design that precisely tapers to the tip. The result is primary radial emission of laser energy with a portion of straight emission, and better access to the narrow part of the periodontal pocket.

This provides more efficient irradiation of diseased or inflamed soft-tissue as well as calculus deposits for treating moderate to advanced periodontal disease.

BIOLASE